

Looking at Second Language Acquisition from a Functional- and Structural MRI Background

Maurits van den Noort (Maurits.Noort@psybp.uib.no)
Department of Biological and Medical Psychology, Jonas Lies vei 91
Bergen, N-5009 Norway

Peggy Bosch (Pbosch@online.no)
Department of Psychiatry and Clinical Medicine, Sandviksleitet 1
Bergen, N-5035 Norway

Kenneth Hugdahl (Hugdahl@psybp.uib.no)
Department of Biological and Medical Psychology, Jonas Lies vei 91
Bergen, N-5009 Norway

Abstract

The question how second and/or third languages are represented in the brain has been the focus of many neuroimaging studies. Some investigators found at least partly different representations for different languages; others reported findings that do not support the hypothesis that different languages are represented in distinct brain regions. However, these different findings can often be explained by differences in experimental set up and by the selection of the bilingual- and multilingual participants. Recently, structural MRI has been used for second language research, as well. Can structural MRI give us a better understanding of the mechanisms behind second and/or third language acquisition? In this paper, functional- and structural neuroimaging data will be discussed in order to answer that question.

Keywords: second language acquisition; functional MRI; PET; structural MRI.

Language Representation

An important question that is asked in many studies is how second and/or third languages are represented in the brain. A major hypothesis is that, in bilinguals and polyglots, the different languages are represented and processed in distinct brain regions. Some indirect evidence for this hypothesis has been found in bilinguals and/or polyglots suffering from aphasia (Paradis, 1989). It was occasionally observed that only one of the mastered languages was affected (Albert & Obler, 1978; Paradis, 1995). Moreover, it is not unusual to find that different languages recover to different degrees or even that there is an antagonistic pattern of recovery between two languages (Paradis, 1977). Neurosurgery as well, may lead to a selective impairment of one language in bilinguals (Gomez-Tortosa et al., 1995). Finally, more evidence in favour of this hypothesis was found in electrical stimulation studies. These studies showed that in multilingual speakers, different languages may be disrupted selectively (Black & Ronner, 1987; Ojemann & Whitaker, 1978; Roux & Trémoulet, 2002).

Recently, PET and fMRI have allowed a more direct study of the neural representation of language in bilinguals and polyglots. However, the pattern that emerges from these neuroimaging studies is far from consistent. In some studies (Dehaene et al., 1997; Kim et al., 1997; Perani et al., 1996; Yetkin et al., 1996), at least partly different representations for different languages were found. In other studies (Hasegawa, Carpenter, & Just, 2002; Hernandez, Dapretto, & Mazziotta, 2001; Illes et al., 1999; Klein et al., 1995) no evidence was found that languages are represented in distinct brain regions. In a few studies (Chee, Tan, & Thiel, 1999; Klein et al., 1999; Pu et al., 2001; Vingerhoets et al., 2003), shared neural substrates were found (Van den Noort et al., 2005b).

Evidently, more research is necessary before any firm conclusions can be drawn. The pattern that emerges from functional neuroimaging studies is far from consistent, which can partially be explained by two major problems: 1) Researchers use different kinds of experimental paradigms, making comparisons between bilingual- and multilingual studies very difficult. 2) The selection of the participants differs. As a result, most of the differences that are found in neuroimaging studies can be explained by differences of the proficiency level, second language onset, and second language exposure of the bilingual- and multilingual participants (Indefrey, to appear). Nevertheless, there are reliable differences between the hemodynamic activation patterns observed during L1 and L2 language processing, but only for subgroups of bilingual speakers and predominantly in the direction of stronger activation during L2 processing (Abutalebi, Cappa, & Perani, 2001; Indefrey, to appear; Stowe & Sabourin, 2005).

Structural Brain Changes

Inferior Parietal Region

Recently, structural MRI has been used for second language research, as well (Van den Noort, Bosch, & Hugdahl, 2005a). It is important to note that structural MRI is not a

competing technique; but must be seen as a useful complimentary approach.

In a study by Mechelli et al (2004), voxel-based morphometry (Ashburner & Friston, 2000; Good et al., 2002) was used to investigate structural plasticity in healthy right-handed English and Italian bilinguals. To test for differences in the density of grey and white matter between bilinguals and monolinguals, they recruited 25 monolinguals who had had little or no exposure to a second language; 25 “early” bilinguals, who had learned a second European language before the age of 5 and who had practised it regularly since; and 33 “late” bilinguals, who had learned a second European language between the ages of 10 and 15 and practised it regularly for at least 5 years. All volunteers for this test were native English speakers of comparable age and level of education.

Voxel-based morphometry revealed that grey-matter density in the inferior parietal cortex was greater in bilinguals than monolinguals (Figure 1a). This effect was significant in the left hemisphere ($p < .05$) and a trend was also evident in the right hemisphere. Although increased grey-matter density in the inferior parietal cortex was common to both early and late bilinguals, the effect was greater in the early bilinguals in the left and right hemispheres. No other significant effects were detected in either grey or white matter.

In addition, they (Mechelli et al., 2004) investigated whether there was a relation between brain structure and proficiency in the second language and age at acquisition. Twenty-two native Italian speakers, who had learned English as a second language when they were between 2 and 34 years old, were tested. Second-language reading, writing, speech comprehension, and production were assessed using a battery of standardized neuropsychological tests. It was found that overall proficiency, as indexed by principal component analysis, correlated negatively with age of acquisition ($p < .01$; $r = -0.855$). Remarkably, voxel-based morphometry revealed that second-language proficiency correlated with grey-matter density in exactly the same left inferior parietal region (Z -score = 4.1; $p < .05$; Figure 1b). In addition, grey-matter density in this region correlated negatively with the age of acquisition of the second language (Z -score = 3.2; $p < .05$; Figure 1c). There were no other significant effects in grey or white matter.

The authors (Mechelli et al., 2004) have therefore identified an increase in the density of grey matter in the left inferior parietal cortex of bilinguals relative to monolinguals, which is more pronounced in early rather than late bilinguals, and have also shown that the density in this region increases with second-language proficiency but decreases as the age of acquisition increases. These effects could result from a genetic predisposition to increased density, or from a structural reorganization induced by experience (Golestani, Paus, & Zatorre, 2002). Early bilinguals probably acquire a second language through social experience, rather than as a result of a genetic predisposition. According to the authors, the findings therefore suggest that the structure of the human brain is altered by the experience of acquiring a second language. Previous second language studies with fMRI had also

shown activation in the inferior parietal region during, for example verbal-fluency tasks (Poline et al., 1996; Warburton et al., 1996). The results that Mechelli et al. (2004) presented are consistent with growing evidence that the human brain changes structurally in response to environmental demands as a function of learning in domains other than language (Draganski et al., 2004; Maguire et al., 2000). Mechelli et al. (2004) therefore concluded that the relationship between grey-matter density and performance that was found in their study could be an example of a more general structure-function principle that extends beyond the domain of language.

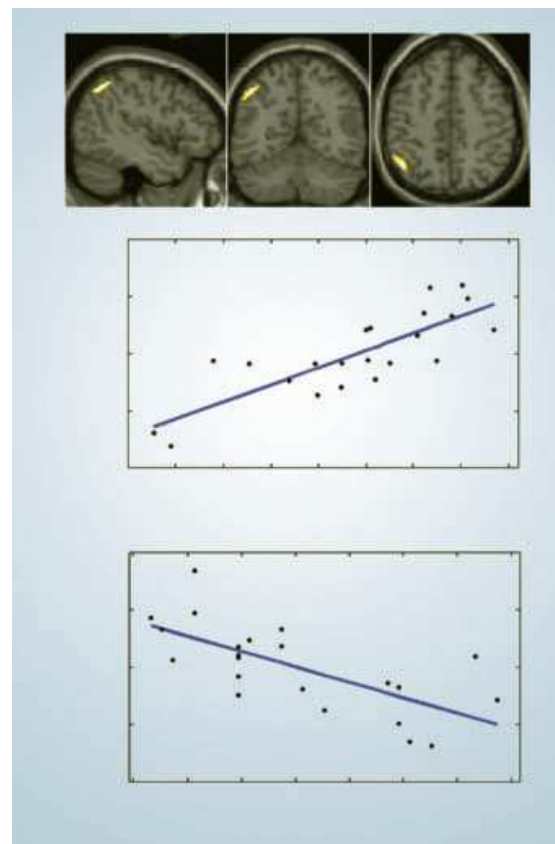


Figure 1: Structural reorganization in the bilingual brain. 1a, Sagittal, coronal, and axial view of the left inferior parietal region, which has increased grey-matter density in bilinguals relative to monolinguals. 1b, Grey-matter density, measured as cubic millimetres of grey matter per voxel in the left inferior parietal region, as a function of second-language proficiency. Second-language proficiency was estimated for each subject from a battery of standardized neuropsychological tests, using principal component analysis. 1c, Grey-matter density, measured as for 1b, as a function of age of acquisition. Adapted from (Mechelli et al., 2004).

The Corpus Callosum

The corpus callosum is another area, in which structural differences between monolinguals and second language learners were found (Coggins, Kennedy, & Armstrong, 2004). What could be the role of the corpus callosum in second language acquisition? (Van den Noort et al., 2005b)

In response to second and/or third language acquisition and use, the human brain undergoes cortical adaptation to accommodate multiple languages either by recruiting existing regions used for the native language, or by creating new cortical networks in distinct adjacent areas of the cortex to handle certain functional aspects of L2. However, regardless of how the cortex organizes the circuitry required to handle multiple languages, all non-reflexive behaviour, including cognition and communication, is normally the result of unconscious and seamless coordination of activity between both hemispheres via the cerebral commissures (Coggins et al., 2004). The corpus callosum is the main fiber tract that connects the two brain hemispheres, which consists of approximately 200-350 million fibers in humans (Aboitiz et al., 1992a, 1992b; Nolte, 1998; Thompson et al., 2002).

Previous research has shown that fibers from the language areas in the superior temporal gyrus (Wernicke's area, planum temporale) pass through the isthmus of the corpus callosum (see Figure 2) (Von Plessen et al., 2002). In addition, Dimond, Scammell, Brouwers, and Weeks (1977) found that the body of the corpus callosum is also specifically involved in language processing. A prominent growth in the language cortex itself was found as well, suggesting a key maturational phase in brain regions that support the learning of new languages.

So far, only one study has been done on corpus callosum variability between monolinguals and bilinguals. In this study, nineteen right-handed adult males and females participated. There were twelve bilingual and seven monolingual participants and they were all teachers. All bilingual participants reported to possess advanced to superior levels of proficiency in the L2 according to the established ACTFL Proficiency Guidelines (American Council for the Teaching of Foreign Languages, 1983). The average age of the bilingual teachers was 38 years (range 25-57); there were 7 females and 5 males. The seven monolingual teachers who participated reported no previous study of a second language and their average age was 45 years (range 29-59); there were 5 males and 2 females. Magnetic resonance imaging (MRI) was the procedure used in this study to produce images of the corpus callosum. A midsagittal section of the corpus callosum was imaged and used for this study. Using a modification of Witelson (1989), the midsagittal corpus callosum image was partitioned plane into five subregions (Figure 2) (Coggins et al., 2004).

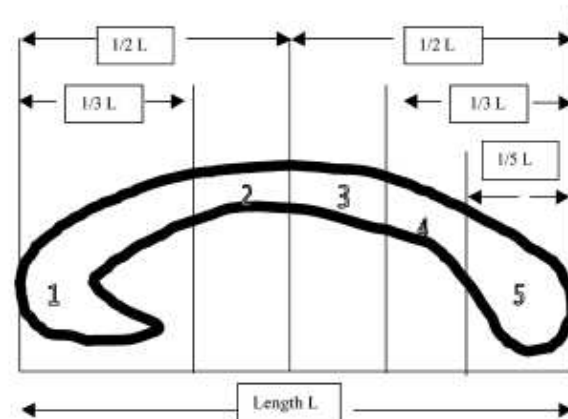


Figure 2: Regional subdivision of the midsagittal corpus callosum. Region 1, anterior third; Region 2, anterior midbody; Region 3, posterior midbody; Region 4, isthmus; Region 5, splenium. Adapted from (Coggins et al., 2004).

The preliminary findings of this study showed significant differences in the corpus callosum between the monolingual and the bilingual groups. The anterior midbody to total corpus callosum midsagittal area ratio was significantly larger in the bilingual individuals compared to the monolingual individuals. This significance should, however, be interpreted cautiously due to the small sample size of the study (Coggins et al., 2004).

More data is needed to test if this difference in the anterior midbody is reliable and to test if the larger posterior midbody to total corpus callosum midsagittal area ratio and the larger isthmus to total corpus callosum midsagittal area ratio are significant if a larger sample size is used. Although more data is needed, the first results seem to be in line with the hypothesis that structural changes in the corpus callosum are taking place during the process of second language acquisition.

Evidence for a Critical Period?

Age of acquisition plays an important role in second language acquisition. An "earlier is better" rule of thumb captures the negative correlation between age of learning onset and eventual asymptotic performance. A considerable body of experimental data is consistent with this generalization. Most of these studies offer a maturational account of age effects and suggest that a critical period limits both L1 acquisition and L2 acquisition (Birdsong & Molis, 2001; Long, 1990).

If a critical period limits second language acquisition, one would expect that linguistic performance should correlate negatively with the age at which L2 learning begins. Importantly, this effect should be observed in cases where L2 learning begins prior to the end of maturation. Moreover, there should be few if any late learners who perform in the range of native controls. Finally, if limits on attainment are maturational in nature, then they should apply to L2 acquisition generally. Johnson and Newport

(1989), proposed their maturational model of L2 attainment based on these lines of reasoning (Birdsong & Molis, 2001).

Johnson and Newport (1989) used a grammaticality judgment task in their experiment. A group of Chinese and Korean learners of English participated in the study. The results of the grammaticality judgment task were in line with the maturational model of L2 attainment. Moreover, Johnson and Newport argued that their results should generalize to other L1 and L2 contexts. Although the findings and interpretations of Johnson and Newport have been widely accepted, there is also evidence against this maturational account.

In some studies, postmaturational age effects were found (Bialystok & Hakuta, 1994, 1999; Birdsong, 1992; Flege, 1999). In other studies, significant numbers of late learners were found, who perform like natives on various linguistic tasks (Bongaerts, 1999; Cranshaw, 1997; Van Boxtel, 2005).

To conclude, the controversy about the existence of a critical period remains as intense as ever (Birdsong, 1999; Hyltenstam & Abrahamsson, 2001; Marinova-Todd et al., 2000; Scovel, 2000; Singleton, 2001; Van Boxtel, 2005; Wartenburger, Heekeren, Abutalebi, Cappa, Villringer, & Perani, 2003). Future structural- and functional MRI research combined with good (psycho)linguistic research could give important results with respect to this debate. In addition, this research could give an answer on the question whether the relationship between grey-matter density (for example in the parietal region and the corpus callosum) and second language performance is indeed only an example of a more general structure-function principle that extends beyond the domain of language as Mechelli et al. (2004) suggested.

General Discussion

Many hypotheses exist about how second and/or third languages are represented in the brain. The pattern that emerges from functional neuroimaging studies is far from consistent. This can partially be explained by the different experimental paradigms that are used in the bilingual- and multilingual studies and by the differences in onset, proficiency, and exposure of the selected participants. So far, reliable differences between hemodynamic activation patterns during L1 and L2 language processing have been observed, but only for subgroups of bilingual speakers and predominantly in the direction of stronger activation during L2 processing (Abutalebi, Cappa, & Perani, 2001; Indefrey, to appear; Stowe & Sabourin, 2005).

Recently, structural MRI has been used for second language research, as well. Are there any structural plastic changes in the human brain during the process of second language acquisition? Is there a specific (second) language acquisition area? In this paper, data on functional- and structural neuroimaging studies were presented to answer these questions. First of all, it is important to note that only two structural neuroimaging studies were conducted, so far. The results of the structural neuroimaging study by Mechelli et al. (2004) are consistent with growing evidence that the human brain changes structurally in response to environmental demands. Structure, is already known to alter

as a function of learning in domains other than language (Draganski et al., 2004; Maguire et al., 2000). Mechelli et al. (2004) conclude that the degree of this structural reorganization in bilinguals is correlated with their second language performance. The relationship between grey-matter density and performance discovered in the study conducted by Mechelli et al. (2004) could be an example of a more general structure-function principle that extends beyond the domain of language.

However, does this mean that there is no specific brain area in which structural changes can be found during the process of (second) language acquisition? The answer to this question is not clear yet. At the end of this paper, we discussed the possible role of another area, namely: the corpus callosum, in which structural differences between monolinguals and second language learners were found. Previous structural neuroimaging research on the corpus callosum (Thompson et al., 2000) showed that fibers from the language areas in the superior temporal gyrus (Wernicke's area, planum temporale) pass through the isthmus area (Von Plessen et al., 2002). Moreover, a prominent growth in the language cortex itself was found, suggesting a key maturational phase in brain regions that support the learning of new languages. In addition, it was found that the body of the corpus callosum is specifically involved in language processing (Dimond, Scammell, Brouwers, & Weeks, 1977).

So far, only one study on corpus callosum variability between monolinguals and bilinguals was conducted. This study showed that the anterior midbody to total corpus callosum midsagittal area ratio was significantly larger in the bilingual individuals compared to the monolingual individuals (Coggins et al., 2004).

Future combined functional- and structural MRI research on bilingualism/multilingualism should give a better insight on the exact role of the inferior parietal region and the corpus callosum, but also on the more specific language areas in the process of (second) language acquisition. Finally, this research could answer the question whether; the relationship between grey-matter density and second language performance is indeed only an example of a more general structure-function principle that extends beyond the domain of language. The other possibility is that it is more second language specific.

Acknowledgments

The authors would like to thank Dr. Peter Indefrey, Dr. Marianne Gullberg, and the other organizers of the *First A. Guiora Annual Roundtable Conference in the Cognitive Neuroscience of Language: The Cognitive Neuroscience of Second Language Acquisition* at the Max Planck Institute for Psycholinguistics, Nijmegen, September 20-21, 2005 for the inspiring discussions.

References

- Aboitiz, F., Scheibel, A. B., Fisher, R. S., & Zaidel, E., (1992a). Fiber composition of the human corpus callosum. *Brain Research*, 598, 143-153.

- Aboitiz, F., Scheibel, A. B., Fisher, R. S., & Zaidel, E. (1992b). Individual differences in brain asymmetries and fiber composition in the human corpus callosum. *Brain Research*, *598*, 154-161.
- Abutalebi, J., Cappa, S. F., & Perani, D. (2001). The bilingual brain as revealed by functional neuroimaging. *Bilingualism: Language and Cognition*, *4*, 179-190.
- Albert, M. L., & Obler, L. K. (1978). *The Bilingual Brain: Neuropsychological and Neurolinguistic Aspects of Bilingualism*. New York, NY: Academic Press.
- American Council for the Teaching of Foreign Languages. (1983). *ACTFL Proficiency Guidelines*. Hastings-on-Hudson, NY: ACTFL Materials Center.
- Ashburner, J., & Friston, K. J. (2000). Voxel-Based Morphometry-The Methods. *NeuroImage*, *11*, 805-821.
- Bialystok, E., & Hakuta, K. (1994). *In other words: The science and psychology of second-language acquisition*. New York, NY: Basic Books.
- Bialystok, E., & Hakuta, K. (1999). Confounded age: Linguistic and cognitive factors in age differences for second language acquisition. In D. Birdsong (Ed.), *Second language acquisition and the Critical Period Hypothesis*. Mahway: Lawrence Erlbaum.
- Birdsong, D. (1992). Ultimate attainment in second language acquisition. *Language*, *68*, 706-755.
- Birdsong, D. (1999). *Second Language Acquisition and the Critical Period Hypothesis*. Mahway: Lawrence Erlbaum.
- Birdsong, D., & Molis, M. (2001). On the Evidence for Maturation Constraints in Second-Language Acquisition. *Journal of Memory and Language*, *44*, 235-249.
- Black, P. M., & Ronner, S. F. (1987). Cortical mapping for defining the limits of tumor resection. *Neurosurgery*, *20*, 914-919.
- Bongaerts, T. (1999). Ultimate attainment in foreign language pronunciation: The case of very advanced later foreign language learners. In D. Birdsong (Ed.), *Second language acquisition and the Critical Period Hypothesis*. Mahway: Lawrence Erlbaum.
- Chee, M. W. L., Tan, E. W. L., & Thiel, T. (1999). Mandarin and English single word processing studied with functional magnetic resonance imaging. *Journal of Neuroscience*, *19*, 3050-3056.
- Coggins, P. E., Kennedy, T. J., & Armstrong, T. A. (2004). Bilingual corpus callosum variability. *Brain and Language*, *89*, 69-75.
- Cranshaw, A. (1997). *A study of Anglophone native and near-native linguistic and metalinguistic performance*. Université de Montréal, Canada.
- Dehaene, S., Dupoux, E., Mehler, J., Cohen, L., Paulesu, E., Perani, D., Van de Moortele, P. F., Lehericy, S., & Le Bihan, D. (1997). Anatomical variability in the cortical representation of first and second language. *Neuroreport*, *8*, 3809-3815.
- Dimond, S. J., Scammell, R. E., Brouwers, E. Y. M., & Weeks, R. (1977). Functions of the centre section (trunk) of the corpus callosum in man. *Brain*, *100*, 543-562.
- Draganski, B., Gaser, C., Busch, V., Schuierer, G., Bogdahn, U., & May, A. (2004). Changes in grey matter induced by training: Newly honed juggling skills show up as a transient feature on a brain-imaging scan. *Nature*, *427*, 311-312.
- Flege, J. E. (1999). Age of learning and second-language speech. In D. Birdsong (Ed.), *Second language acquisition and the Critical Period Hypothesis*. Mahway: Lawrence Erlbaum.
- Golestani, N., Paus, T., & Zatorre, R. J. (2002). Anatomical correlates of learning novel speech sounds. *Neuron*, *35*, 997-1010.
- Gomez-Tortosa, E., Martin, E., Gaviria, M., Charbel, F., & Ausam, J. (1995). Selective deficit of one language in a bilingual patient following surgery in the left perisylvian area. *Brain and Language*, *48*, 320-325.
- Good, C. D., Scahill, R. I., Fox, N. C., Ashburner, J., Friston, K. J., Chan, D., Crum, W. R., Rossor, M. N., & Frackowiak, R. S. J. (2002). Automatic differentiation of anatomical patterns in the human brain: validation with studies of degenerative dementias. *NeuroImage*, *17*, 29-46.
- Hasegawa, M., Carpenter, P. A., & Just, M. A. (2002). An fMRI study of bilingual sentence comprehension and workload. *Neuroimage*, *15*, 647-660.
- Hernandez, A. E., Dapretto, M., & Mazziotta, J. (2001). Language switching and language representation in Spanish-English bilinguals: an fMRI study. *Neuroimage*, *14*, 510-520.
- Hyltenstam, K., & Abrahamsson, N. (2001). Age and L2 learning: hazards of applying unestablished "facts". Comments on Stefka H. Marinova-Todd, D. Bradford Marshall and Catherine E. Snow's "Three Misconceptions about Age and L2 Learning". *TESOL Quarterly*, *35*, 151-170.
- Illes, J., Francis, W. S., Desmond, J. E., Gabrieli, J. D. E., Glover, G. H., Poldrack, R., Lee, C. J., & Wagner, A. D. (1999). Convergent cortical representation of semantic processing in bilinguals. *Brain and Language*, *70*, 347-363.
- Indefrey, P. (to appear). A meta-analysis of hemodynamic studies on first and second language processing: Which suggested differences can we trust and what do they mean? In M. Gullberg & P. Indefrey (Eds.) *The Cognitive Neuroscience of Second Language Acquisition*. Malden, MA: Blackwell Publishing.
- Johnson, J. S., & Newport, E. L. (1989). Critical period effects in second language learning: The influence of maturational state on the acquisition of English as a second language. *Cognitive Psychology*, *21*, 60-99.
- Kim, K. H., Relkin, N. R., Lee, K. M., & Hirsch, J. (1997). Distinct Cortical Areas Associated with Native and Second Languages. *Nature*, *388*, 171-174.
- Klein, D., Milner, B., Zatorre, R. J., Meyer, E., & Evans, A. C. (1995). The neural substrates underlying word generation: a bilingual functional-imaging study.

- Proceedings of the National Academy of Sciences of the United States of America*, 92, 2899–2903.
- Klein, D., Miller, B., Zatorre, R. J., Zhao, V., & Nikelski, J. (1999). Cerebral organization in bilinguals: a PET study of Chinese–English verb generation. *Neuroreport*, 10, 2841–2846.
- Long, M. H. (1990). Maturation constraints on language development. *Studies in Second Language Acquisition*, 12, 251–285.
- Maguire, E. A., Gadian, D. G., Johnsrude, I. S., Good, C. D., Ashburner, J., Frackowiak, R. S. J., & Frith, C. D. (2000). Navigation-related structural change in the hippocampi of taxi-drivers. *Proceedings of the National Academy of Sciences of the United States of America*, 97, 4398–4403.
- Marinova-Todd, S. H., Marshall, D. B., & Snow, C. E. (2000). Three misconceptions about age and L2 learning. *TESOL Quarterly*, 34, 9–34.
- Mechelli, A., Crinion, J. T., Noppeney, U., O’Doherty, J., Ashburner, J., Frackowiak, R. S., & Price, C. J. (2004). Structural plasticity in the bilingual brain. *Nature*, 431, 757.
- Nolte, J. (1998). *The human brain: An introduction to its functional anatomy*. St. Louis: Mosby.
- Ojemann, G. A., & Whitaker, H. A. (1978). The bilingual brain. *Archives of Neurology*, 35, 409–412.
- Paradis, M. (1977). Bilingualism and aphasia. In: H. Whitaker & H. A. Whitaker (Eds.), *Studies in Neurolinguistics* (pp. 65–121). New York, NY: Academic Press.
- Paradis, M. (1989). Bilingual and polyglot aphasia. In: F. Boller & J. Grafmann. (Eds.), *Handbook of Neuropsychology* (pp. 117–140). Amsterdam: Elsevier.
- Paradis, M. (Ed.) (1995). *Aspects of Bilingual Aphasia*. New York, NY: Elsevier.
- Perani, D., Dehaene, S., Grassi, F., Cohen, L., Cappa, F. S., Dupoux, E., Fazio, F., & Mehler, J. (1996). Brain processing of native and foreign languages. *Neuroreport*, 7, 2439–2444.
- Poline, J. B., Vandenberghe, R., Holmes, A. P., Friston, K. J., & Frackowiak, R. S. J. (1996). Reproducibility of PET Activation Studies: Lessons from a Multi-Center European Experiment EU Concerted Action on Functional Imaging. *NeuroImage*, 4, 34–54.
- Pu, Y., Liu, H. L., Spinks, J. A., Mahankali, S., Xiong, J., Feng, C. M., Tan, L. H., Fox, P. T., & Gao, J. H. (2001). Cerebral hemodynamic response in Chinese (first) and English (second) language processing revealed by event-related functional MRI. *Magnetic Resonance Imaging*, 19, 643–647.
- Roux, F. E., & Trémoulet, M. (2002). Organization of language areas in bilingual patients: a cortical stimulation study. *Journal of Neurosurgery*, 97, 857–864.
- Scovel, T. (2000). A critical review of the critical period research. *Annual Review of Applied Linguistics*, 20, 213–223.
- Singleton, D. (2001). Age and second language acquisition. *Annual Review of Applied Linguistics*, 21, 77–89.
- Stowe, L., & Sabourin, L. (2005). Imaging the processing of a second language: Effects of maturation and proficiency on the neural processes involved. *International Review of Applied Linguistics in Language Teaching*, 43, 329–354.
- Thompson, P. M., Gied, J. N., Woods, R. P., MacDonald, D., Evans, A. C., & Toga, A. W. (2000). Growth patterns in the developing brain detected by using continuum mechanical tensor maps. *Nature*, 404, 190–193.
- Thompson, P. M., Narr, K. L., Blanton, R. E., & Toga, A. W. (2002). Mapping Structural Alterations of the Corpus Callosum during Brain Development and Degeneration. In E. Zaidel, & M. Iacoboni (Eds.), *Proceedings of the NATO ASI on the Corpus Callosum*. Kluwer Academic Press.
- Van den Noort, M. W. M. L., Bosch, M. P. C., & Hugdahl, K. (2005a). Understanding the role of working memory in second language acquisition. *Proceedings of KogWis05 The German Cognitive Science Conference 2005* (pp. 144–149). Basel: Schwabe.
- Van den Noort, M. W. M. L., Nordy, H., Bosch, M. P. C., & Hugdahl, K. (2005b). Understanding Second Language Acquisition: Can Structural MRI bring the Breakthrough? *Proceedings of the International Conference on Cognitive Systems*. New Delhi: NIIT.
- Van Boxtel, S. (2005). *Can the late bird catch the worm? Ultimate attainment in L2 syntax*. Utrecht: Landelijke Onderzoekschool Taalwetenschap (LOT).
- Vingerhoets, G., Van Borsel, J., Tesink, C., Van den Noort, M. W. M. L., Deblaere, K., Seurinck, R., Vandemaele, P., & Achten, E. (2003). Multilingualism: An fMRI study. *NeuroImage*, 20, 2181–2196.
- Von Plessen, K., Lundervold, A., Duta, N., Heiervang, E., Klauschen, F., Smievoll, A. I., Ersland, L., & Hugdahl, K. (2002). Less developed corpus callosum in dyslexic subjects: a structural MRI study. *Neuropsychologia*, 40, 1035–1044.
- Warburton, E., Wise, R., Price, C., Weiller, C., Hadar, U., Ramsay, S., & Frackowiak, R. (1996). Noun and verb retrieval by normal subjects: Studies with PET. *Brain*, 119, 159–179.
- Wartenburger, I., Heekeren, H. R., Abutalebi, J., Cappa, S. F., Villringer, A., & Perani, D. (2003). Early setting of grammatical processing in the bilingual brain. *Neuron*, 37, 159–170.
- Witelson, S. F. (1989). Hand and sex differences in the isthmus and genu of the human corpus callosum: A post-mortem morphological study. *Brain*, 112, 799–835.
- Yetkin, O., Yetkin, Z., Haughton, V. M., & Cox, R. W. (1996). Use of functional MR to map language in multilingual volunteers. *American Journal of Neuroradiology*, 17, 473–477.